

Study of Incidence in Number of Renal Hilar Structures [Artery, Vein, Pelvis] in Human Cadaveric Kidney

Uday Kumar*, Ratna Prabha*, Vishal Salve**

Abstract

Background and Aims: The advent of more conservative methods in the renal surgery has necessitated a more precise knowledge of renal vascularisation at the renal hilum and it has its importance in partial and total nephrectomy and also in renal transplantation surgeries. This study is mainly aiming at the incidence in the number of renal hilar structures [renal artery, vein and pelvis]. **Material and Methods:** Totally 84 kidneys were studied in the present work by blunt dissection method. These 84 kidneys were collected from department of Anatomy, Navodaya medical college and hospital, some were formalin stored and some freshly dissected from cadavers during the routine dissection classes of medical students. The incidence of no. of renal artery, vein and pelvis were observed. **Results:** Out of 84 kidneys studied, single renal artery was seen in 72 specimens and 12[14.28%] specimens showed double renal arteries coming separately from abdominal aorta and entering separately at the upper part and lower part of hilum. Double renal veins were seen in 3 specimens [3.57%]. These renal veins were coming out of hilum and passing in front of renal artery and entered the inferior venecava. Only one kidney [1.19%] showed double pelvis which was coming out of kidney separately from posterior upper and lower part of hilum and joined just before opening into the urinary bladder. **Conclusion:** The knowledge of such variations in number of structures is important in carrying out renal surgeries.

Keywords: Kidney; Number; Renal Artery; Vein; Pelvis.

Introduction

Kidney is the pair of bean shaped excretory organs situated retroperitoneal in the lumbar region on either side of vertebral. The kidney has two borders; Lateral border which is convex and medial border is concave and shows a deep vertical fissure known as hilum, which is bounded by anterior and posterior lips. Here is the passage of renal vessels, pelvis of ureter, lymphatic's and nerves [1]. Normally we have single renal artery, vein and pelvis at the hilum and their positions from anterior to posterior are renal vein, renal artery and renal pelvis in that order.

The present work was undergone to know the incidence of any extra renal vessels and pelvis. This

study can improve the safety of newer percutaneous intrarenal access by intact as many renal vessels as possible during the percutaneous puncture, thus preventing the through and through puncturing of artery and collecting system. The increase in no. of renal vessels may compress the renal pelvis thus creating complications like hydronephrosis.

In 70% individuals there is a single renal artery to each kidney [1]. The artery divides into anterior and posterior division near the hilum. And there is single renal vein lying anteriorly extends from hilum to inferior venecava, the left is longer than right [2].

The upper end of ureter expands to form the pelvis of kidney. The single renal pelvis comes out through the posterior part of the hilum posterior to renal vessels [1].

In 1552, Eustachio's [2] described a case of multiple renal arteries, he also made the first copper plate engravings illustrating renal artery variations. In 1714 Lanciisi [3] published the engravings with commentary and referred to the variations as a "lusus nature" or sport of nature. In 1901, Harvey [4] reported a case of bilateral multiple renal arteries and

Author's Affiliation: Assistant Professor*, Professor & Head**, Department of Anatomy, Navodaya Medical College Hospital, Raichur, Karnataka.

Corresponding Author: Uday Kumar, Assistant Professor, Department of Anatomy, Navodaya Medical college and Hospital, Mantralayam road, Raichur, 584103. Karnataka.
E-mail: doctoruday@gmail.com

renal veins. Nation [5] in his series of autopsy studies of 16000 cases found the following types of duplication of ureter- Unilateral complete duplication of ureter in 78 cases, Unilateral partial duplication in 99 cases, bilateral complete duplication in 35 cases and partial bilateral duplication in 19 cases. Prasad et al [6] reported association of a bifid ureter with presence of unilateral pulmonary hypoplasia likewise Gunduz et al [17] found a duplex ureter associated with presence of Golts syndrome. Pushpa Dhar et al [8] in their routine dissection revealed 2 right renal veins where artery was sandwiched between the two renal veins and another study by same authors with corrosion cast method showed multiple renal veins were common on the right side. So like this many authors have studied only variation of single structures at the renal hilum. Here my study is regarding variation in no. of renal artery, vein and pelvis and this study is useful information for urosurgeons, radiologists and academic importance to Anatomy teachers.

Material and Methods

The present work was conducted in department of Anatomy at Navodaya medical college and hospital. Totally 84 kidneys [42 pairs] was collected from the department. All the kidneys were cleaned by doing the blunt dissection method by using forceps and scissors. The kidneys were looked for fullness of

specimen, any cut kidney specimens were excluded from the study. Finally selected kidney specimens were numbered with number plates and observed for the number of renal vessels and pelvis at the hilum. The kidney showing the double renal artery, renal vein and pelvis were coloured [red for artery, blue for vein and yellow for pelvis] and photographed. Relevant data were recorded and analysed statistically (manually).

Results

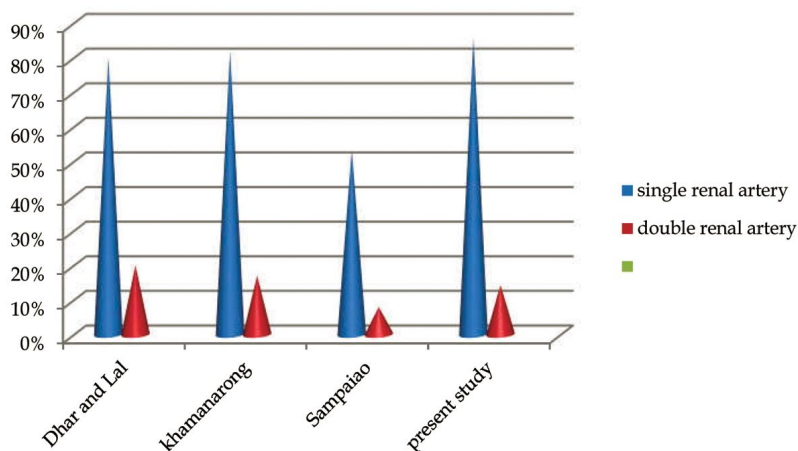
Out of 84 kidney specimens, 12 specimens [14.28%] showed double renal artery, which were arising separately from abdominal aorta and entered the renal hilum at the upper and lower part of the hilum [Fig1]. The two renal arteries were named as upper and lower renal artery [Table No. 1 and Graph No.1]

Out of 84 kidneys, 3 specimens [3.57%] showed double renal veins which were coming out of renal hilum at the upper and lower part of it [Fig 2]. These veins were ending separately into inferior venacava. Double renal veins were seen only on the right side. In the same specimens the left renal vein was single [Table No. 2 and Graph No. 2].

Out of 84 kidneys, only one kidney [1.19%] showed duplex pelvis which continued as double ureters, but both of them joined and entered the urinary bladder with single opening [Fig 3]. The duplex was seen on the left side of renal pelvis [Table No. 3 and Graph No. 3].

Table 1: incidence of single and double renal artery in present study and other authors

Sl. no	Authors	Single renal artery[%]	Double renal artery[%]
1.	Dhar and Lal [8]	80	20
2	Khamanarong [33]	82	17
3	Sampaiao F J [34]	53.3	7.9
4.	Present study	85.71	14.28



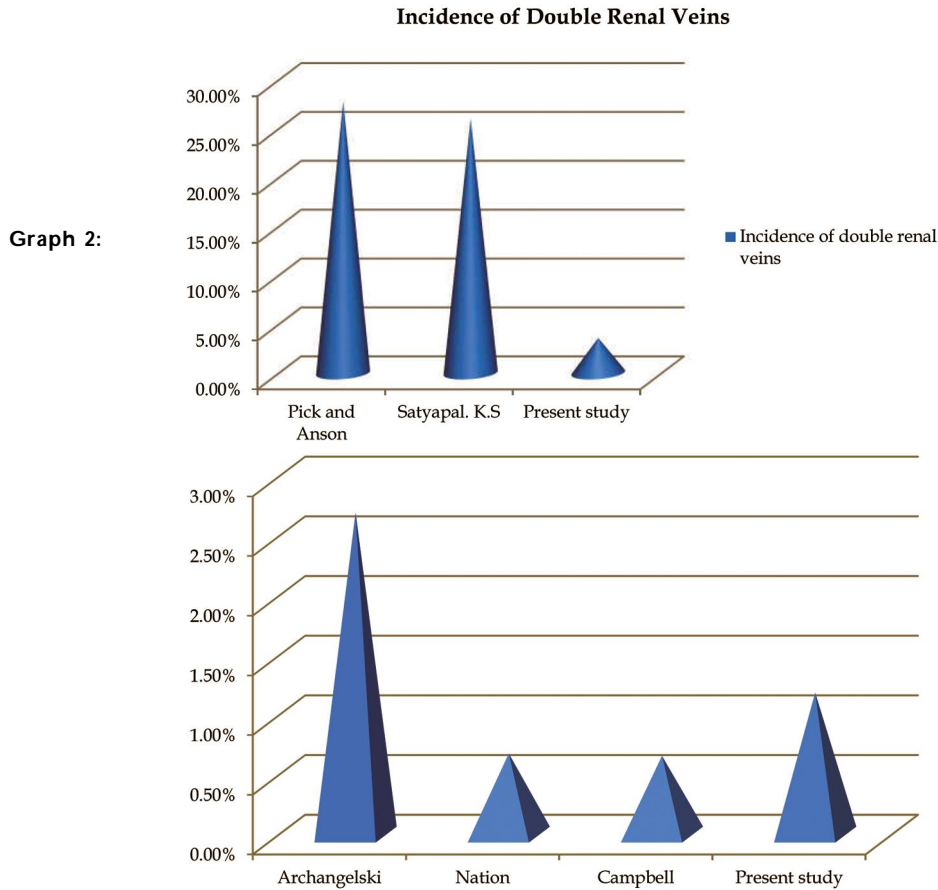
Graph 1: showing incidence of single and double renal artery in present and other studies

Table 2: Incidence of double renal veins and comparison with other authors

Sl. No.	Authors	Incidence of Double Renal Veins
1.	Pick and Anson [25]	27.8%
2.	Satyapal. K.S [35]	26%
3.	Present study	3.57%

Table 3: Incidence of duplication of pelvis in present study and its comparison with other authors

Sl. No.	Authors	Incidence of Duplication [%]
1.	Archangelski [28]	2.7%
2.	Nation [5]	0.68%
3.	Campbell [32]	0.66%
4.	Present study	1.19%



Graph 3: incidence of duplication of pelvis in present study and its comparison with other authors

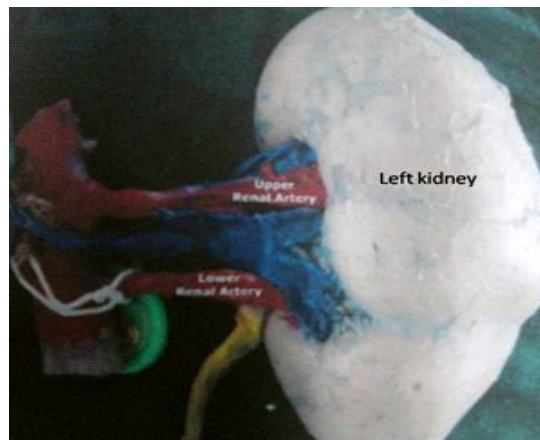


Fig. 1: left kidney showing double renal arteries

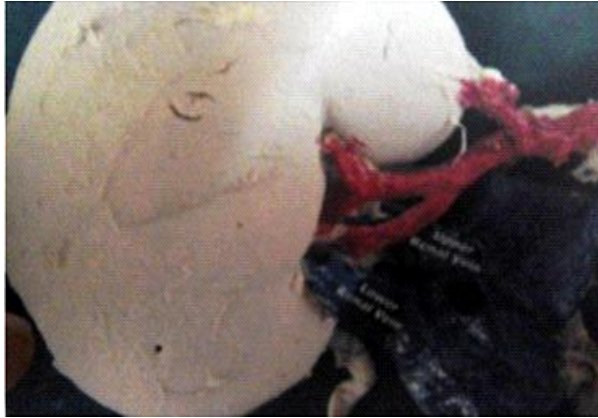

Fig. 2: right kidney showing upper and lower right renal veins

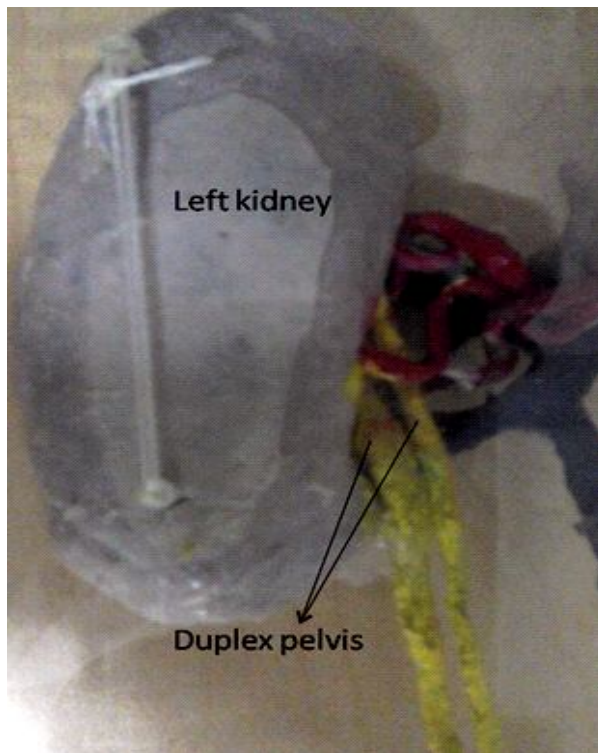


Fig. 3: left kidney showing duplex pelvis[left kidney posterior view]

Discussion

Kidney is the pair of excretory organs present retroperitoneally in paravertebral position at the lumbar region. The kidney has single renal artery, renal vein and pelvis at the hilum in 70% of individuals [1]. Many earlier authors have reported the supernumerary vessels and duplex, triple pelvis which were because of the insults or disturbance during the development of kidneys and its vasculature. The renal arteries originate from the abdominal aorta and account for 20% of cardiac output to the kidney [1]. The renal vascular

segmentation was discovered by John Hunter [9] in 1794, but detailed account was given in 1950's by F T Graves [10] corrosion cast method. There are five defined arterial segments: apical, superior, middle, inferior and the posterior. In 1920, an extensive study done by Daniel N Eisendrath [11] in different series of studies found—5 out of 124 kidneys had double renal arteries. Riichiro Toda [12] and his colleagues operated upon a 72 old man with an abdominal aortic aneurysm and found double left renal vein forming a ring around aorta. Another case reported by Bayramoglu *et al* [13] which showed bilateral double renal arteries in a 68 year old male cadaver. In 2005 Verma *et al* [14] reported a case of double renal veins with double testicular veins. The two renal veins draining separately into IVC. Another study done in 2005 by R.M.P Fernandes [15] and his colleagues found 3 renal veins draining the right kidney, they named it as superior right renal vein [SRRV], middle right renal vein [MRRV], inferior right renal vein [IRRV] according to the location when draining into IVC.

The Anatomical knowledge of multiple renal arteries is essential before performing any transplantation surgeries, where microvascular techniques are employed to reconstruct the renal arteries [16]. The embryological basis of these variations has been presented and discussed by Keibel F and Mall FP [17]. In a 18mm fetus, the developing mesonephros, metanephros, suprarenal glands and gonads are supplied by nine pair of lateral mesonephric arteries arising from dorsal aorta. Felix [17] divided these arteries into three groups as follows: the 1st and 2nd arteries as the cranial group, the 3rd and 4th arteries as the middle group and 6th and 9th arteries as caudal group. The middle group gives rise to renal arteries. Persistence of more than one renal arteries of the middle group results as multiple renal arteries. So duplicated renal arteries are due to persisting lateral mesonephric arteries from the middle group. Further Sharmista Biswas *et al* [18] reported a case of variation of renal and testicular veins in their routine dissection, on the right side there was an additional renal vein that drained directly into IVC. Ugur Ozkan *et al* [19] studied abdominal angiography of 855 patients, there was single renal artery in 76% of the patients. Multiple renal arteries were found in 202[24 %] cases, more than one renal artery on right side in 135 cases [16%] and left side in 113 cases [13%].

Madhur Gupta *et al* [20] reported a horseshoe kidney, right side kidney was drained by three veins directly into IVC. Timothy K *et al* [21] operated on a 55 year old female who was referred for gross hematuria and planned for laparoscopic left radical nephrectomy. Upon hilar dissection, the IVC was

encountered without visualization of aorta. In additional 3 renal veins were encountered. The surgery was uneventful and kidney was removed successfully.

Nayak B. S et al [22] found a case where right kidney showed three arteries, superior renal artery was divided into three branches and middle and inferior renal arteries were divided into 2 branches each. The right kidney also showed 2 renal veins of equal size. According to Testut and Latarjet [23] and Bergmann et al [24] the renal veins show less variation than renal arteries and studies done by Pick and Anson [25] found supernumerary arteries are seen in 32.25% of kidneys and supernumerary veins are seen in 14.4% so that supernumerary arteries seem to be at least twice as common as supernumerary arteries. In the present study also double renal arteries were seen in 14.28% of cases and double renal veins were seen in 3.57% of cases [Table No. 1 and 2], so this study results are reporting that multiple arteries incidence are thrice more than the multiple veins and thus also supports the sentence that supernumerary arteries are common than supernumerary veins, as told by earlier authors.

Renal Pelvis

Renal pelvis is the upper expanded part of ureter. Malformations of urinary system are relatively common comprising about 3% of live births [1]. The reported incidence of ureteral duplication varies widely among different series depending on the clinical data, survey or autopsy. Duplication of pelvis and the ureter results from early splitting of ureteric bud [23]. Splitting may be partial or complete, ureteric may divide before penetrating the metanephric tissues, thus giving rise to a bifid ureter having a single opening into the bladder. In case of very early division of ureteric bud, there is incorporation of ureteric division into posterior aspect of urogenital sinus which results in duplication of ureter with separate orifices for each. Bifid ureter unless symptomatic might be detected during investigations or incidental findings at autopsy. Sometimes there are features of reflux and as a result urinary calculi [26], pyelonephritis and ureterohydronephrosis develop [27].

In 1926, Archangelski [28] in his series of studies of ureter by radiological method [619 cases] and autopsy method [3 cases] found that unilateral duplication of ureter was 502 cases [80%] and bilateral duplication in 117 cases [20%]. Out of 4215 autopsies done by Lowsly et al [29], there were 18 cases of incomplete duplication among them 2 were

bilaterally incomplete, 7 were unilaterally incomplete and 9 were unilaterally complete duplicate. Ochoa Urdangarian et al [30] reported a complete triple ureter and a 27 year old female patient consulted for episodes of right renal colic, several studies including intravenous urography and CT scans were performed revealing a right renal lithiasis and double ureteral pyelocaliceal system on the right side, the left kidney showed 3 pyelocaliceal system with 3 ureters each of them draining separately into the bladder. Gawlik Jkubczak T et al [31] evaluating a case of hypertension by ultrasound which revealed a giant hydronephrosis with double pelvis and ureter on left side. Nation [5] observed 109 cases of duplication of ureter in 16000 autopsies with an incidence of 0.68% where as Campbell [32] in his personal series of 51,880 autopsies observed 342 ureteric duplication with rate of 0.66%. Combining Nation [5] and Campbell [32] series the projected incidence of duplication is 1 in 125 or 0.8%, unilateral duplication is more common than the bilateral duplication. In our present study [Table No. 3] also, out of 84 kidneys only one kidney showed duplication of pelvis and ureter which accounts to be 1.19% which is close to the studies done by Nation [5] and Campbell [32] series of autopsies.

Conclusion

By this study it can be reported that supernumerary arteries are more common than supernumerary veins and duplication of pelvis though the incidence is less in this study, the urologist and radiologist should keep in mind of such duplications and supernumerary vessels. This present study is an attempt to add an interest in multiple renal vessels and duplex pelvis and to add to the knowledge of surgeons and radiologist for a betterment of their diagnosis and treatment of patients.

References

1. Standring Susan, Ellis H, Healey J. Kidney and ureter. Grays Anatomy, The anatomical basis of clinical practice. 39th ed. Elsevier- Churchill Livingstone publishers, London. 2005; 1274-1275.
2. Eustachius 1552, Illustrated encyclopedia of Human anatomic variation OPUS II; Cardiovascular/text/arteries/abdomen.
3. Lancisii, 1714, Illustrated encyclopedia of Human anatomic variation OPUS II; Cardiovascular/arteries/abdomen.

4. Harvey W. Anatomy for surgeons. 3rd edition vol 2, Harper and Row, Philadelphia, 1982; pg544.
5. Nation series of studies [1944], table no.116-2, ureteral duplication:clinical radiological and autopsy studies. Text book of urology.pg 3415.
6. Prasad R, Mukerji P.K, Kant S, Singh A K, Narain V S. Indian journal of chest diseases and allied sciences. 1996; (38): 205-9.
7. Gunduz K, Gunalp I, Erden I . Bifid ureter in Goltz syndrome.ophthogenetics. 1997; 18: 143-9.
8. Pushpha Dhar. Double renal veins- a case report. Clinical Anatomy. 2002; 15: 64-66.
9. John Hunter. Vasculature of body. British journal of surgery. 1794; 38: 1-8.
10. Graves F T. The anatomy of intrarenal arteries and its application to segmental resection of the kidneys. British journal of surgery. 1952; 42: 132-40.
11. Daniel N E.Chicago . Illustrations; the relation of variations of renal vessels to pyelotomy and nephrectomy. America urological association Newyork city. 1920.
12. Riichiro T, Yoshifumi I, Yukinori M, Yosuke H, Hiroshi M, Ryuzo S. Double left renal vein associated with abdominal aortic aneurysm. Ann Thoracic Caediovascular surgery. 2001; 7(2): 113-5.
13. Alp Bayramoglu, Deniz Demiryurek, Kadriye M, Erbil. Bilateral additional renal arteries and additional right renal vein associated with unrotated kidneys. Saudi medical journal. 2003; 24(5): 535-537.
14. Verma R , Kalra S, Rana K. Malformation of renal and testicular veins- A Case report. Journal of Anatomical society of India. 2005; 54(1): 29-31.
15. Fernabdez R. M. P, F H P Conte, L A Favorito, M Abidu Figueiredo M, A Babinski. Triple right renal vein: an uncommon variation. International journal of morphology. 2005; 23(3): 231-33.
16. Brannen G E, Bush W H, Correa R J, Gibbons R P, Cumes D M. Microvascular management of multiple renal arteries in transplantation. J Urolo, 1982; 128(1): 112-15.
17. Keibel F, Mall F P (eds). Manual of human embryology, vol2, J.B Lippincott, Philadelphia.1912; 820-25.
18. Sharmistha B, J C Chattopadhyay, Panicker H, Anbalagan J, S K Ghosh. Variation in renal and testicular veins- a case report. Journal of Anatomical society of India. 2006; 55(2): 69-71.
19. Ugur Ozkan, Levent O, Fahri Tercan, Osman K, Zafer K, Nihal K. Renal artery origins and variations: angiographic evaluation of 855 consecutive patients. Diagno interven Radiology. 2006; 12: 183-86.
20. Madhur Gupta, Ajay Kumar, Neeru G. Horseshoe kidney-a case report, Nepal medical college journal. 2007; 9(1).
21. Timothy K B, Grant I S D, Ihor S Sawczuk, Ravi munver, Vascular anomolies during laparoscopic renal surgery: incidence and management of left sided inferior venacava . Journal of the society of laporoendoscopic surgeons. 2009; 13: 77-79.
22. Nayak B S. Multiple variation if the right renal vessels – a case report, Singapore medical journal. 2008; 49(6).
23. Testut L, Latarjet A. Tratado de anatomia humana(1947)8th ed, salvat editories, Barcelona.
24. Bergmann R A, Afifi AK, Miyauchi R, Renal arteries: Illustrated encyclopedia of Human Anatomic variation: opus II: Cardiovascular: arteries: Abdomen [2005].
25. Pick J W, Anson B J. The renal vascular pedicle. An anatomical study of 430 body halves. J Urology. 44: 411-34.
26. Giannokopoulos X, Chambilomatis P, Thirothoulakis M, Seferiadis G. The blind ending bifid ureter . Internal urology and nephrology. 1994; 26: 161-5.
27. Chalouhy E, Harram R, Ezzo G. Various aspects of uretero uretero reflux in incomplete ureteral duplication.Journal of medicine.libnan. 1994; 40: 16-21.
28. Archangelski. Ureteral duplication,clinical radiological and autopsy studies. Text book of Urology, Table no 116-2, pg3415.
29. Lowsly O S, Kiwori T J. clinical urology. The William and wilkins company.USA (1956).
30. Ochoa U O, Hermida P J A, Monte de ojo, Miranda R F, Rivero G C. complete triple ureter- a case report , spain anat journa. 2006; 59(3): 284-87.
31. Gawlik J T, Moczynski W, Darczynski M, Krajka K. Giant hydronephrosis of the upper left kidney in case of complete one sided double pelvis. Journal anatomy. 2006; 63(5): 306-08.
32. Campbell textbook of urology, table no116-2, ureteral duplication:clinical,radiological and autopsy studies.pg3415.
33. Khamanarong K, Prachney P, Utraravichen A, Tong-Un T, Sripaoraya K. Anatomy of renal arterial supply, clinical anatomy. 2004; 17(4): 334-36.
34. Sampaio F J, Passos M A. Renal arteries:anatomic study for surgical and radiological practice, Surg Radio Anat, 1992; 14(2): 113-17.
35. K.S. Satyapal. Classification of drainage pattern of renal veins. Journal of Anatomy. 1995; 186: 329-33.